ORIGINAL ARTICLE **Mirror of Research in Veterinary Sciences and Animals MRVSA/ Open Access DOAJ**

Mirror of Research in Veterinary Sciences and Animals (MRVSA) / Journal homepage: http://mrvsa.com/
E-ISSN 2307-8073; 2520-324X (Print)

Morphological, Histological and Histochemical Study of trachea of One Hump Camel (*Camelus dromedaries)* In South of Iraq

Adel Jabbar Hussein [1]; Ibrahem A. Abdul Zahra [2*]

[1] Department of Anatomy and histology, veterinary medicine college, university of Basra, Iraq.[2] College of science, Al Muthanna university of/ Iraq

ARTICLE INFO
Received: 05.04.2016
Revised: 10. 06.2016
Accepted: 12.06.2016
Publish online: 25.06.2016

***Corresponding author:**
Email address:
ibrahemabdulrasol@gmail.com

Abstract

The objective of this study was to describe the morphological, histological and histochemical structural features of the trachea of the camel (*Camelus. dromedaries*) Tracheas from 10 adult male camels aged between 3-5 years were collected from slaughter house in Al- samawa and Al- zubair distract. This study were performed at college of veterinary medicine / university of Basra. Clinically, all camels were appeared normal and healthy. The length, and the number of tracheal cartilage rings were measured and processed for histological study. The morphological study revealed that the mean length of the trachea was 95 ± 0.77 cm, while the mean number of the cartilage rings was 75.6 ± 0.74. The histological results revealed that the wall of trachea consist of mucosa, submucosa, hyaline cartilage and adventitia. The mucosa was lined by respiratory epithelium (pseudostratified ciliated columnar epithelium) with numerous goblet and basal cells, while the lamina propria was consisted of loose connective tissue. Muscularis mucosa was very thin layer, while the submucosa appeared as a layer of loose connective tissue and contained tubulo - acinar submucosal glands, which were very few in number and small in size. The hyaline cartilage layer was surrounded by perichondriun with the dense fibroblastic tissue presented between the cartilaginous rings**.** The adventitia was consisted of connective tissue with numerous elastic fibers. On the other hand the Periodic acid–Schiff stain (PAS) showed a positive reaction of gobblet cells and submucosl gland.

To cite this article: Adel Jabbar Hussein; Ibrahem A. Abdul Zahra. (2016). Morphological, Histological and Histochemical Study of trachea of One Hump Camel (*Camelus dromedaries*) In South of Iraq. MRVSA 5 (Special issue) 1st Iraqi colloquium on camel diseases and management. 19-25.
DOI: 10.22428/mrvsa. 2307-8073.2016. 005SI3.x

Keywords: One humped camel, Trachea, Histology, Periodic acid–Schiff stain

Introduction

Camels are in the taxonomic order Artiodactyls (even toed ungulates), sub order Tylopoda (pad-footed), Family camilidae which has two species *Camelus dromedarius* (one humped) and *Camelus bacterianus* (two humped) (Klingel, 1990).The camel is

considered as a very important animal, but it had received little attention when compared with other species of animals **(**Khattal *et al.*, 2015**)**. Respiratory system plays important role in olfaction, phonation and regulation of body temperature (Sellnow 2006; Baba and Choudhary, 2008).

The lower respiratory tract include the trachea, bronchi, bronchioles and the lungs. Trachea is a flexible tube composed of cartilaginous rings, connected by a fibromuscular membrane and lined internally by mucosa. It is composed of several of C-shaped tracheal cartilages in different species, which are open dorsally and the space is bridged by tracheal muscle (Dabanoglu and Kara, 2001). The structures of respiratory tract are varied among species and within each species (Legaspi, 2010) .The trachea is composed of respiratory epithelium that surrounded by a submucosa and well-developed subtending adventitia with incomplete cartilaginous rings (Samuelson, 2013).

The purpose of this study was to describe the morphological, histological and histochemical structure of trachea of *C. dromedarius* using the routine and special histological stains.

Materials and Methods

Tracheas of ten adult male camels (*C. dromedarius*) were used for this study. The trachea of apparently normal and clinically healthy camels were collected from Al Samawa and Al Zubair abattoirs. These tracheas were dissected and flushed with normal saline. The treachea was dividing into three equal parts (proximal, middle and distal part) for morphological study. Lengths of the trachea were measured from the cranial border of the first tracheal ring to the tracheal bifurcation. In addition, the number of tracheal rings were also counted. By incising the tracheal annular ligaments, the transverse diameters, vertical diameters, and cartilage thickness were measured by using a ruler and digital caliper with an accuracy of ±0.02mm. (Tempest, 1980). For histological examination, the samples were fixed in 10% neutral bufferd formalin for 72 h. Tissue samples were then dehydrated in a graded alcohol, cleared in xylol and embedded in paraffin wax. Each paraffin block was sectioned at (6µm) micrometers thickness and stained with haematoxylin and eosin, Masson's trichrome and Van Giesson for collagen fibers, and periodic acid schiff stain (PAS) for histochemistry of muco-substances**.(** Luna,1968)

Result and Discussion

The results of this study showed that the trachea consisted of the installation of tubular shape made up of sequentially series of cartilaginous rings incomplete dorsally in the gross examination. The rings were connected with each other by annular ligament and their ring edges were close by the tracheal muscle at their internal surface (Figure.1). Trachea was lined with relatively thick mucous membrane. The length of trachea from the first to the last tracheal ring was 92-101cm with a mean value of 95 ± 0.77 cm. These results are disagree with previous study (Al-Zghoul *et al*, 2007). Al-Zghoul *et al.*, (2007) reported the tracheal length (87 ± 0.83 cm) in young Arabian camels with differences due to variation in the age. The number of the tracheal rings were varied from 72-79 with a mean value of 75.6 ± 0.74. This result is compatible with similar values which was

reported previously for the adult Indian camels (Kumar *et al.*, 1992). However, this result is disagreed with (Cano and Perez, 2009), who described the trachea of giraffe and mentioned that it has (87-100) ring due to the length of the neck. The variation in numbers of tracheal rings between specimens was due to individual anatomical variations (Nickel *et al.*, 1979). The diameters of tracheal rings was determined by calculation the mean diameter for three tracheal region.

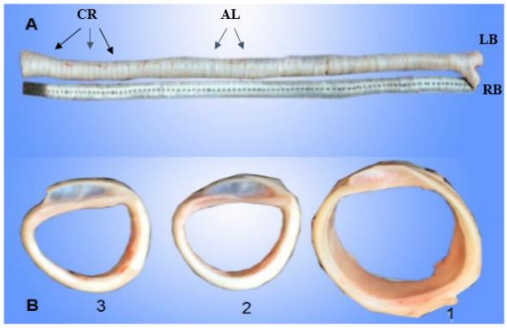

Figure .1: **A-** Shows the dorsal view of treachea, showing: (CR) cartilage ring, (AL) annular ligament, (LB) left primary bronchi, (RB) right primary bronchi. **B-** Shows the cross section of three part of trachea, showing: (1) proximal part was semi-oval shape and the end of rings have relatively large opening laterally to appear as C-shape,(2) middle part of treachea the end of the rings is overlapping the left end on right end ,(3) distal part treachea the end of the rings is overlapping the left end on right end . The means of proximal transverse, proximal vertical, middle transverse, middle vertical, distal transverse and distal vertical were 34.46±0.48 mm 41.98±0.32 mm, 29.85±0.25 mm 30.48±0.18 mm and 24.72±0.09 mm and 26.68±0.24 mm respectively. The mean value of tracheal rings thickness for three part (proximal, middle and distal) are 6.55±0.03, 5.19±0.12, 3.92±0.07 mm respectively. The lumen of the trachea narrowing toward distal part with relatively degrees in thickness and bounded by bone such as first pair of ribs, vertebra (thoracic vertebra) and sternum which acts to facilitating movement of neck . Tracheal ring fusion with neighboring rings was observed within all different tracheal regions. Fusion of the tracheal rings occurred mostly in the cranial cervical region. It has been suggested that tracheal rings of this region are most affected by neck movements resulting in its fusion over time (Morgan *et al.*, 1986). The shape of tracheal rings in the proximal part was semi-oval and the end of rings have relatively large opening laterally to appear as C-shape. In the middle part of trachea, the end of the rings was overlapping the left end on right end continuously with the distal part of the trachea, and each ring connected with next ring.

The histological examination from the proximal, middle and distal part of the trachea revealed that the wall of the trachea consist of mucosa, submucosa, hyaline cartilage and adventitia, (Figure. 2). The luminal surface was completely covered by cilia, which is similar to cattle, goat and neonatal kids (Abdel-Rahman, 1999). The mucosa was lined by pseudostratified ciliated columnar epithelium with numerous goblet and basal cells, goblet cells and basal cells. All these cells were rest on the basement membrane but not all of them reach the luminal surface, and their nuclei disposed at different levels (Figure. 3).These results are similar to those observed in most mammalian species (Ibe *et*

al.,2011) , in the sheep (Mariassy *et al.*,1983) ,in the goat (Kahwa and Purton,1996). The ciliated columnar cells were one of the most abundant cell types appeared as a tall columnar cells, with cilia covering their apical surfaces and extending into the tracheal lumen (Figure.2). Their cytoplasm was slightly stained with large oval shaped nuclei located near the epithelial surface (Figure.2). Similar features was observed in Yak (Yang *et al.,* 2010). Goblet cells produce exclusive amounts of acidic and neutral muco-substances (Figure.3).

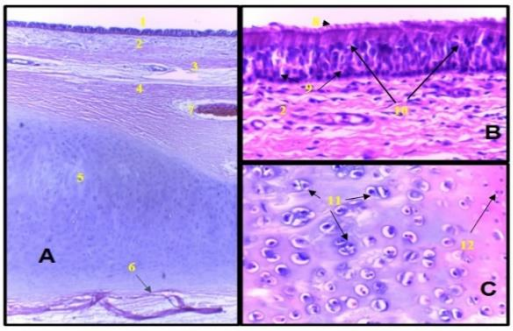

Figure. 2: Cross section of trechea of adult camel showing**:A-** The wall of the trachea.1- pseudostratified ciliated columnar epithelium. 2- Lamina propria. 3- Muscularis mucosa. 4- Submucosa consist of loose connective. 5- Hyaline cartilage. 6- Adventitia. 7- Blood vessel. (H&E stain 40X). **B-** 8-cilia. 9- Basal cell. 10- Goblet cell. (H&E stain 400X). C – Hyaline cartilage 11- chondrocytes inside the lacuna. 12- Perichondrium. (H&E stain 400X)

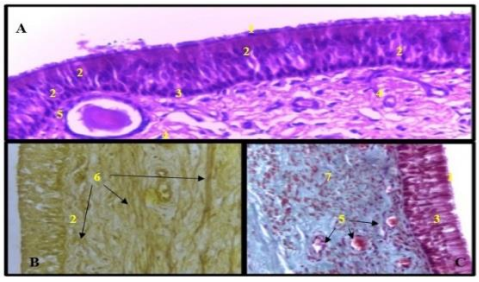

Figure (3) Cross section of trachea of adult camel showing:
A-1 – pseudostratified ciliated columnar epithelium
2- goblet cell 3- Basel cell 4- blood vessel 4- lamina propria .(H&E 400X)
B- 6- Lamina propria with elastic fibers. (Van Gieson stain.400X).
C-7- Lamina propria with prominent collagen fibers, (Masson's trichrome stain. 400X).

In contrast, goblet cells in goat produce acidic mucosubstances, which is observed by Kahwa and Purton, (1996). The goblet cells showed appositive reaction toward PAS stain and revealed purple color due to mucopolysaccharide contents (Figure.4) .Similar finding was observed by Raji and Naserpour, (2007). The mucous produced by goblet cell act as a protective barrier for the epithelium by lubricating, insulating and providing an appropriate condition for mucociliary clearance (Buchner and Maxwell, 1993). Lamina propria were loose connective tissue with prominent collagen and elastic fibers, blood

vessels and lymphatic vessels (Figure.4). These features are similar to the histological features of cats and goats (William, 1990). The muscularis mucosa was very thin layer consist of few smooth muscle fibers (Figure.3) and such result comparable with the those found in cat Nasser(2012). The tunica submucosa appears as a layer of loose connective tissue contains different connective tissue cells, lymphocytes, monocytes, macrophage and plasma cells, blood vessels and the submucosal glands were very few in number,small in size and appeared as tubulo - acinar mucus type glands that were appositively reacted with PAS (Figure.4) .The glands opened into the lumen of trachea by a slit shaped duct (Figure.4). Similar features was also reported previously by Choi and Finkbeiner, (2000). The tracheal muscle was smooth and lied internal to the open end of the horseshoe-shaped hyaline cartilage as seen in other ruminants. It is noteworthy that tracheal muscle lies external to the cartilages in the carnivores (Nickel and Schumer, 1979). (Figure. 4). The hyaline cartilage layer was surrounded by perichondriun with the dense fibroblastic tissue present between the cartilaginous rings, it contain the chondrocytes inside the lacuna within an amorphous matrix (Figure.2).The adventitia was consisted of connective tissue with numerous elastic fibers that are similar to cat (William, 1990).

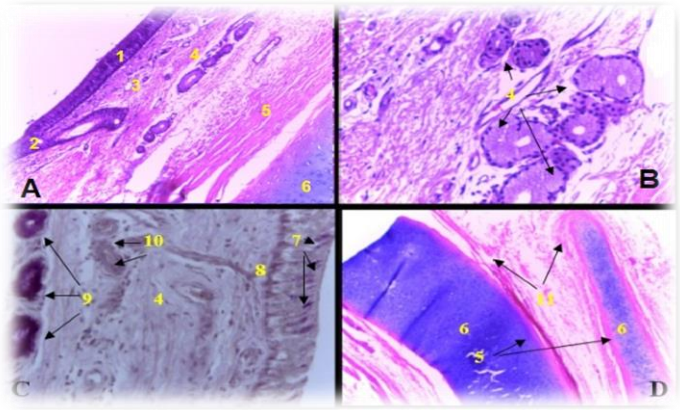

Figure (4) Cross section of trechea of adult camel showing:
1- The ciliated columnar cells. 2- Slit shaped duct of submucosal gland 3- Lamina propria. 4- submucosal gland which tubulo - acinar mucus type. 5- Perichondrium. 6- Hyaline cartilage. (H&E 40X).
B- 4- submucosal gland which tubulo - acinar mucus type. (H&E 400X).
C- 7- goblet cell, which appear positive reaction for PAS giving rise to purple color. 8- Basement membrane. 9- Positive reaction for PAS of submucosal gland. 10- Blood vessel. (PAS 400X)
D- 11- Trachealis muscle was smooth muscle fiber and lied internal to the open end of the hyaline cartilage. (H&E 100X).

References

Abdel-Raouf A A Khattal, Moukhtar H Gad Moussa, Mohamed H A Kandil, Laila R Abdel-Salam, Wail A Elhawari and Abeer H Amer. (2015): Micromorphological Studies Of Type-I Pneumocytes In The Pulmonary Alveoli Of The Lung Tissue Of The

One-humped Camel (Camelusdromedarius).Journal Of Basic Medical And Allied Sciences; 1;doaj.

Al-Zghoul M F, Ismail Z B, Al-Rukibat R K and Al-Majali AM. (2006). A Quantitative Study On The Trachea of Young Arabian Camels *(Camelus dromedarius)*. Journal of Camel Practice and Research, *13 (2*), *p 129-133.*

Baba MA and Choudhary A R. (2008).Histomorphological of the Pulmonary Alveoli of Goat (Capra hircus).Division of Veterinary Anatomy & Histology, Faculty of Veterinary Sciences & Animal Husbandry Veterinary World, SKUAST-K, Shuhama Campus, Alusteng, Srinagar Vol.1(10): 312-313.

Buechner M, Maxwell V. (1993). Normal respiratory epithelia structure and function, Comp Cont.Ed, Vet.15:612-625.

Cano I and Perez W. (2009). Quantitative anatomy of the trachea of the Giraffe Int.J. Morphol, 27(3):905-908.

Choi H K, and Finkbeiner W E. (2000) A comparative study of mammalian tracheal mucous glands. J. Anat. 197, 361–372.

Dabanoglu MK and Kara ME. (2001). A quantative study on the trachea of dog .Anat .Histol .Embryol .30: 57-59.

Dellman H D. (1998). Textbook of Veterinary Histology, 4th edn. Philadelphia: LEA and Febiger. 148–163.

Don A Samuelson. (2006). Textbook of Veterinary Histology. W.B. Saunders Company. pp 231-232.

Ibe C S, Onyeanusi B I, Salami S O and Nzalak J O. (2011). Microscopic anatomyof the lower respiratory system of theAfrican giant pouched rat (Cricetomysgambianus, Waterhouse 1840). Int. J. Morphol. 29(1):27-33.

Kahwa C K B, and Purton M. (1997): Scanning electron microscopic observation of the path morphology of the distal airways and alveolar region in the goat. Small Rum. Res. 34: 223–231.

Kahwa CK, Atwal OS, Purton M. (1997). Transmission electron microscopy of the epithelium of distal airways and pulmonary parenchyma of the goat lung. Res Vet Sci. 63(1):49-56.

Klingel H. (1990): Camels in Grzimek's Encyclopedia of Mammals. New York: MC Graw-Hill.

Kumar P, Singh G, Nagpal SK and Dhingra LD. (1992). Tracheal Journal of Camel Practice and Research dimensions of camel. Indian Journal of Animal Science 62:140-141.

Legaspi M, Authier S, Gauvin D, Moreau M, Beauchamp G, Chaurand F, Troncy E. (2010). Respiratory safety pharmacology: concurrent validation of volume, rate, time, flow and ratio variables in conscious male Sprague–Dawley rats. Regul. Toxicol. Pharmacol. 58, 444–45010.1016/j.yrtph.2010.08.014

Luna LG. (1968). Manual histologic staining methods of the armed forces institute of pathology. Third edition .New York Toranto London Sydney. (94).

Mariassy AT Plopper CG. (1983). Tracheobronchial epithelium of the sheep: Quantitative light-microscopic study of epithelial cell abundance, and distribution. Anat Rec.; 205:263–275.

Morgan JP, Miyabayashi T and Choy S. (1986). Cervical spine motion: Radiographic study. American Journal of Veterinary Research 47(10):2165-2169.

Nassar RA. (2012). Anatomical and histological study on the lower respiratory system in the local cats M.SC. Thesis. Coll. Vet. Med. Baghdad Uni.

Nickel R and Schumer A. (1979). The Viscera of the Domestic Mammals. Berlin, Hamburg: Verlag Paul Parey.

Raji A R and Naserpour M. (2007): Light and electron microscopic studies of the one-humped camel (camelus dromedaries). Anat. Histol. Embryol. 36: 10-13.

Sellnow L. (2006). Blood and breath the circulatory and respiratory system work together to fuel the horse's body. Am. Assoc. Equ. Vet. Tech., 93-98. Www. The horse. Com.the horse November.

Tempest DH. (1980) .Anatomical Technieques.2ed.edition.Roy College of surgeons of England Edinburgh and London. (126-127).

William J. (1990): Color Atlas of Veterinary Histology. Lea &Febiger. pp 161–177.

Yang B Sijiu, Yan YU, Junfeng C, Xinhua HE, JI, Andru W. (2010). Histochemical and Ultrastructural Observations of Respiratory Epithelium and Gland in Yak. (Bosgrunniens) Faculty of Veterinary Medicine, The anatomical record 293:1259–1269.